



Surgical Management of Locoregional Recurrence in Breast Cancer

Ashish Goel¹ · Varun Kumar Agarwal¹ · Vikash Nayak¹ · Rekha Yogsrivas¹ · Abhishek Gulia¹

Received: 28 October 2020 / Accepted: 29 April 2021
© Indian Association of Surgical Oncology 2021

Abstract

Locoregional recurrences from breast cancer represent a heterogeneous group of disease that poses a therapeutic challenge and needs a multidisciplinary team management. The incidence of local recurrence after breast conservation surgery ranges from 10 to 22% and 5–15% after mastectomy at 10-year follow-up. Management of locoregional recurrence depends on tumor biology, stage at presentation, and prior local and systemic therapy. With improvements in diagnostic, pathological, and surgical techniques, radiation and systemic therapy approach, outcomes in these patients have improved. In this review, we discuss the risk factors, prognostic factors, surgical and reconstruction options, re-irradiation, and role of systemic therapy to define a reasonable treatment approach without compromising oncologic safety and achieve good cosmetic and survival outcomes.

Keywords Recurrent breast cancer · Redo breast conservation surgery · Salvage mastectomy · Re-irradiation

Introduction

Breast cancer is the most frequently diagnosed cancer and the leading cause of cancer death in females worldwide. After treatment of primary breast cancer, locoregional recurrence poses a therapeutic challenge. Local recurrences are more common in younger patients, BRCA 1/2 carriers, large tumor size, node-positive disease, high-grade tumors, and hormone receptor negative or Her-2-positive tumors. Treatment-related factors for local recurrence include presence of unrecognized multifocal/multicentric disease at presentation, incomplete excision of primary with positive surgical margins, lymphovascular space invasion, and omission of adjuvant radiotherapy or systemic therapy [1].

Recurrences tend to occur later after BCS (breast conservation surgery) as compared to mastectomy (median 3–4 years vs. 2–3 years, respectively) [2]. The time to recurrence may be even longer (5–7 years) after BCS in patients who receive adjuvant tamoxifen and/or chemotherapy [3]. The 10-year incidence of locoregional recurrence after BCS is 3–5% for

patients who received adjuvant radiation and up to 35% for those who did not [4].

In-breast tumor recurrences (IBTRs) after BCS are detected by mammography while postmastectomy recurrences are typically diagnosed by physical examination. In-breast local recurrence after BCT may be either true recurrence or second primary tumor. Tumors within 3 cm of primary bed and with similar morphology are usually true recurrences and tend to be more aggressive with shorter overall survival and breast cancer-specific survival compared to second primary cancers. Regional nodes and chest wall are most likely sites of postmastectomy failures and are associated with higher rates of simultaneous distant metastases and poorer cause-specific survival.

Local recurrence after BCS may be either invasive or carcinoma in situ. In patients initially treated for invasive disease, more than 80% of locoregional recurrences are invasive while the remainder may be intraductal lesions. Although 75% are solitary and confined to breast, 5–15% may present with regional nodal recurrence or distant metastases at time of diagnosis [5].

The interval between initial diagnosis and recurrence is the most consistently documented prognostic factor [6]. Disease-free interval of at least 2 years is associated with significantly better outcome. Overall survival rates and long-term local control are dependent upon the site and volume of the disease recurrence [7].

✉ Ashish Goel
dr_ashishgoel@yahoo.com

¹ Department of Surgical and Radiation Oncology, Jaypee Hospital, Noida, India

Clinical and Staging Evaluation of Locoregional Breast Recurrence

In-breast tumor recurrences are detected as palpable mass on physical examination in 10–30% cases while surveillance mammography detects 40–75% and magnetic resonance imaging (MRI) detects recurrences in around 5% cases [8]. Around 50% of IBTRs detected on physical examination are mammographically occult; therefore, normal mammogram should always be supplemented with physical examination. Patients can also present with palpable adenopathy in axilla or supraclavicular fossa, or with brachial plexopathy or lymphedema of the arm.

Initially, FNAC may be done to differentiate scar from recurrent lesions; however, tissue biopsy is necessary to get hormone receptor and human epidermal growth factor receptor over expression. Retrospective studies have shown overall 70% and 65% concordance in ER and PR status between primary and recurrence tumor respectively [9].

All patients should be evaluated by routine blood tests and computed tomography (CT) of the chest, abdomen, and pelvis to screen for metastatic disease. The most common site of unsuspected disease is in internal mammary lymph nodes. Radionuclide bone scan is necessary even in asymptomatic patients as bone is the most common site of metastatic disease.

Contrast-enhanced MRI to distinct between tumor recurrence and radiation-induced fibrosis especially for patients with brachial plexopathy or arm edema without obvious adenopathy is often necessary.

PET/CT is being used in lieu of bone scintigraphy and dedicated CT scanning to survey the entire body for sites of distant metastasis. However, PET scans have high false-positive rate (approximately 11% in a pooled analysis) and should be used selectively [10].

Surgery for Postmastectomy Local Recurrence

In postmastectomy patients with chest wall recurrences, there are no consensus guidelines regarding further surgical management and treatment largely depends on location, extent and depth of recurrent lesion, status of residual skin flaps, and prior radiation therapy (Fig. 1). Whenever feasible, wide excision of recurrent chest wall lesions, with or without excision of underlying muscle, is indicated with local or distant flaps. Neoadjuvant systemic therapy or radical radiotherapy may be an option for unresectable cases with diffuse chest wall recurrences. In a retrospective analysis of 44 patients with isolated chest wall recurrent lesions who underwent surgical excision with curative intent, the median overall survival (OS) was 4.8 years with projected 5-year OS of 45% for the entire cohort [11]. Another study from Germany showed a median survival of 3.4 years for patients with isolated chest wall

recurrence who underwent surgical excision [12]. Patients in whom local recurrence was identified by physical examination had a significantly shorter 5-year disease-free survival compared with patients with detection by mammography alone (73 vs. 91%) [13].

Surgery for Post BCS Local Recurrence

Management of IBTR in patients with previous breast conservation surgery (BCS) depends on initial adjuvant radiotherapy, performance status of patient, and presence of metastatic disease. Approximately 15% patients with IBTR may not be suitable for revision due to presence of locally extensive recurrence or inoperable regional nodal or metastatic disease [14].

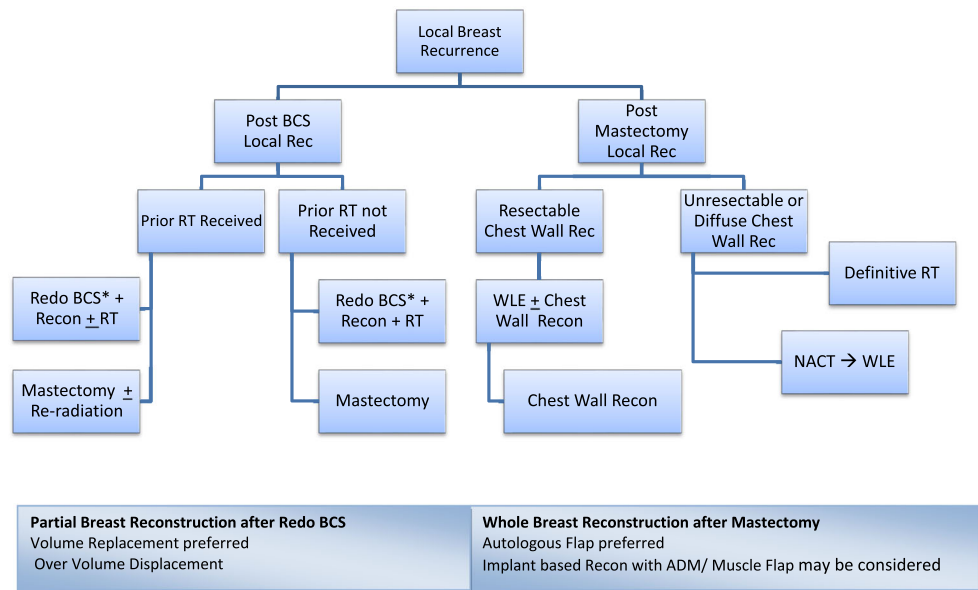
Although salvage mastectomy is the standard of care for surgical management of post BCS local recurrences, redo BCS followed by RT (if not received earlier) is also an option. In a prospective study of 146 patients with IBTR, there was no significant difference in 10-year survival rates and local recurrence for patients treated with redo BCS as compared with patients treated with mastectomy [15].

In a retrospective review of 79 patients, better 5-year actuarial local control rates were seen in patients treated with redo BCS followed by adjuvant RT as compared to those who did not receive radiation [16]. In patients who underwent primary BCS and adjuvant radiation therapy, redo BCS is offered only to selected patients with small localized recurrence in concordance with mammogram and physical examination, longer time to relapse after initial surgery, and feasibility of re radiation. This fact is supported by a retrospective review of 161 patients with IBTR after initial BCS. Patients treated with redo BCS for recurrent tumors ≤ 2 cm and > 48 -month time to relapse had significantly fewer second recurrences compared with tumors > 2 cm and < 48 -month time to relapse (15.2 vs. 31.2%). [17] Patients who carry *BRCA1/2* mutation or have risk of multicentric IBTR may not be suitable candidates for redo BCS.

Management of the Axilla

Axillary evaluation should begin with thorough physical examination and ultrasound with fine needle aspiration (FNA) biopsy of any clinically suspicious lymph nodes. In case of recurrent axillary lymph nodes in patients who previously underwent sentinel lymph node biopsy (SLNB), formal level I and II axillary lymph node dissection (ALND) is performed, while axillary exploration with resection of recurrent nodes is performed if ALND was previously done. Patients with no clinical evidence of recurrent regional disease do not need re-exploration of axilla. The decision for revision axillary

Fig. 1 Surgical management for recurrent breast cancer



surgery and adjuvant therapy should be taken after multidisciplinary tumor board discussion.

In patients who have IBTR and underwent initial ALND, generally SLNB is not undertaken as detection of sentinel node may be difficult due to prior surgery and radiation therapy. Recently there is an interest in role of repeat SLNB after previous ALND, particularly when lymphoscintigraphy is added to identify sites of non-axillary drainage. The Sentinel Node and Recurrent Breast Cancer (SNARB) study group analyzed 239 patients with unsuccessful rSLNB. Sixty patients underwent further ALND, and only eight patients (13%) were found to have macro-metastases in one or more lymph nodes. At a median follow-up of 5.1 years, none of these patients had a regional recurrence. There was no difference in 5-year DFS (90.8% vs. 91.1%, $p = 0.980$) in the two groups. The study supported no further ALND for patients who do not have successful mapping in rSLNB [18].

Treatment of Isolated Axillary Recurrences

Isolated axillary recurrence may occur in 1–3% cases after adequate management of primary disease [19]. Initial clinical approach is to rule out distant metastases followed by resection of recurrent disease. Patients with inoperable regional nodal recurrences have less favorable outcome than those with potentially resectable axillary disease. Use of triple modality and surgical management of axillary recurrences were significantly associated with higher axillary control rates following recurrences. In a retrospective study from the Netherlands for axillary recurrent lesions, surgical intervention was done in 70% of patients with axillary control in 58% and 5-year actuarial OS of 39% [20].

In the patients who had not received RT after primary treatment, adjuvant RT is recommended; however, data proving the benefit for same is very less. Due to higher rates of lymphedema and brachial plexopathy, some institutions withhold RT except for unresectable axillary nodes.

Treatment of Supraclavicular Recurrences

The patients with isolated supraclavicular recurrences have less favorable outcome as compared to those with isolated axillary recurrence. Multidisciplinary evaluation and management are essential in all cases. Systemic therapy is preferred initially followed by reassessment for local treatment. Both surgery and RT can be considered for disease control, depending on the volume of residual disease, magnitude of response, and expected morbidity of both therapies. Surgery alone can be done if RT was previously given, while RT alone may be used if the area was not previously irradiated. A combination approach can also be used if there has been an incomplete response to chemotherapy. Lukens et al. in their analysis found out that approximately 15-30% of patients with isolated supraclavicular recurrence appear to have a good PFS and OS, and should be treated with curative intent [21].

Oncoplastic Breast Reconstruction After Redo BCS

Oncoplastic breast surgery (OBS) has emerged as an integral component of breast-conserving surgery to achieve optimal oncologic outcome and cosmesis. OBS allows for excision of tumor with wider surgical margins without compromising cosmetic and esthetic outcomes with similar oncologic

efficacy compared to conventional BCS without OBS. There is emerging role of OBS in patients undergoing repeat lumpectomy for ipsilateral local recurrence after prior BCS and radiation therapy [22].

Whole-Breast Reconstruction After Salvage Mastectomy

Patients with primary or recurrent breast cancer undergoing mastectomy should be considered for whole-breast reconstruction as it has been found to be oncologically safe. There have been significant advances in surgical techniques which allow satisfactory reconstruction of breast. Patient preference and lifestyle are very important when planning reconstructive breast surgery. Several factors which need to be considered when considering a patient's suitability for breast reconstruction include age, comorbidities, body mass index, smoking history, diabetes, steroid/other drug therapy, and religious affiliation.

Issues with Adjuvant Radiotherapy and Breast Reconstruction

Breast reconstruction in previously irradiated patients often presents a challenge due to higher risk of surgical complications and reconstruction failures. Autologous flaps remain the best option in post-radiotherapy patients although implant reconstruction may be done in selected patients. The choice of reconstruction (implant vs. autologous flap) and timing of surgery (immediate vs. delayed) are debated due to concerns of radiation changes in skin flaps as a result of prior radiotherapy or need for adjuvant radiotherapy following reconstruction. A systematic review of 14 studies with effects of pre reconstruction radiation and 23 studies on post reconstruction radiation evaluated complication rates and did not find any difference in incidence of reconstruction failures and completion rates in both pre and post reconstruction radiation patients. The authors suggested similar overall success and failure rates with radiotherapy given both before and after reconstruction [23].

Autologous flaps such as transverse rectus abdominis myocutaneous (TRAM) and latissimus dorsi (LD) myocutaneous flaps are considered safer with use of pre or post reconstruction radiotherapy compared to implant-based reconstruction. The bi-pedicled TRAM flap allows for sufficient tissue for reconstruction after resection of radiated recipient skin and provides improved blood supply to the recipient bed [24].

Several studies have reported higher complications with implant reconstruction after mastectomy for recurrent breast cancer compared to primary mastectomy and reconstruction.

Cordeiro et al. reported early complication rate of 29.7% in 121 patients with prior BCS and radiation compared with 15.5% in 1578 patients with no prior breast surgery [25]. Similar results were demonstrated by Lam et al. [26]

In 2017, Chetta et al. compared postoperative morbidity in 4781 patients receiving adjuvant radiotherapy after breast reconstruction with implant or autologous flaps. The implant-based reconstruction group had higher overall complications (45.3% vs. 30.8%, $p < 0.001$) and higher implant failures (29.4% vs. 4.3%) respectively compared to autologous flaps. The highest probability of reconstruction failure was in patients with delayed implant reconstruction and in patients with prior radiation (37.2%) and lowest with immediate autologous reconstruction with post reconstruction radiation (3.5%). The study concluded significant morbidity and implant failures in patients previously exposed to radiotherapy [27].

To improve the results of implant reconstruction after radiotherapy, a good muscular coverage of prosthesis with LD flap or acellular dermal matrix (ADM) should be considered in order to create a pocket for tissue expander/implant and allow quicker tissue expansion with better coverage and definition of the lower pole of breast. In 2016, a systematic review suggested the benefit of LD flap to cover the prosthesis in irradiated field. Thirty-one studies involving 1275 breast reconstructions were included, and six studies compared implant loss rates for LD-assisted implant reconstruction vs. implant only reconstruction. The LD-assisted reconstruction had the lowest implant loss (5%) compared to 15% with submuscular only reconstruction ($p < 0.001$), lower wound infection rate (4% vs. 6%, $p = 0.007$), and significantly lower reoperation rates (15% vs. 33%, $p < 0.001$) [28].

Deep inferior epigastric artery perforator (DIEP) flap reconstruction is the gold standard for abdominal wall-based microvascular flap breast reconstruction. In a study by O'Connell et al., aesthetic outcome and patient satisfaction rates in women undergoing DIEP flap in setting of postmastectomy radiotherapy (PMRT) were analyzed prospectively. Patients who did not undergo post reconstruction radiotherapy had better aesthetic outcomes and had higher satisfaction scores when compared with patients with PMRT. The decision to perform immediate DIEP flap reconstruction in patients requiring PMRT needs patient counseling due to higher post reconstruction complications and flap failures after radiation therapy. [29] Pearson et al. studied the effects of radiotherapy in 125 patients who underwent immediate DIEP reconstruction. In all patients requiring PMRT, adequate preoperative, intraoperative, and postoperative steps were taken to ensure flap vascularity and limit radiation damage to breast mound. At a median follow-up of 18 months, there was no clinically significant fat necrosis in either group and all patients had satisfactory aesthetic outcomes. The authors concluded that immediate DIEP flaps could be performed successfully in patients requiring PMRT if steps were taken to

ensure flap vascularity, minimize fibrosis, optimize contour, and modulate radiation dose [30]. Similarly Taghizadeh et al. in their analysis of patient outcomes in 112 immediate DIEP flap did not find any significant increase in complication rate with PMRT [31].

Role of Radiation and Re-Irradiation in Breast Cancer Recurrences

Generally whole-breast irradiation is recommended after redo BCS in radiation naïve patients. In patients already treated with prior radiotherapy, the decision for re-irradiation is challenging due to increased risk of normal tissue morbidity (soft tissue necrosis, rib and lung damage, and cardiac toxicity for left-sided lesions). Standard external beam radiation therapy or catheter-based interstitial brachytherapy can be delivered to previously radiated breast without significant side effects in most patients and with acceptable cosmesis. Pilot studies have supported the role of interstitial brachytherapy or partial breast radiation in selected patients with small size recurrence or relapse >4 years after primary treatment with local control rates ranging from 57 to 95% with acceptable acute toxicity [32]. Another study of 39 patients with IBTR who underwent redo BCS followed by multicatheter pulse dose rate (PDR) brachytherapy found 93% 5-year actuarial local control rate and OS and DFS of 87 and 77% respectively [33].

Role of re-irradiation in patients who develop chest wall recurrence and have undergone prior mastectomy with adjuvant radiotherapy is less clear. Due to long-term toxicity, full-dose re-irradiation is generally not considered although retreatment of limited volumes with decreased total radiation dose may be considered to maximize the opportunity for optimal local control. Local control rates of nearly 70% at 1 year have been noted in a small series of patients undergoing limited field re radiation to site of recurrent disease [34]. However, if re-irradiation is undertaken in these circumstances, precautions should be taken to reduce dose to critical structures like the ribs, heart, and lung. Electron beams or hyper-fractionated RT may be used to reduce significant late side effects.

Role of Systemic Therapy

Although five National Surgical Adjuvant Breast and Bowel Projects enrolling 2669 patients (B-15, B-16, B-18, B-22, and B-25) have showed higher risk of distant metastases and increased likelihood of death following isolated locoregional recurrence, role of chemotherapy following adequate local treatment of LRR remains controversial.

In the Chemotherapy as Adjuvant for Locally Recurrent (CALOR) breast cancer trial, 162 patients who underwent excision of isolated locoregional recurrence were randomly

assigned to post-excision chemotherapy or to no chemotherapy. Chemotherapy improved 10-year DFS and OS in patients who were hormone receptor negative as compared to receptor-positive patients [35].

Women with ER-positive disease should be treated with a different endocrine regimen than what she had received in the past (irrespective of whether chemotherapy was administered or not). Therefore, women previously on tamoxifen may be offered switch to aromatase inhibitor (AI) if postmenopausal, or ovarian suppression and aromatase inhibitor, if premenopausal. Fulvestrant can be offered to those previously treated with AI. A randomized trial evaluating the benefit of endocrine therapy in locally recurrent breast cancer assigned 167 patients with hormone receptor-positive or hormone receptor-unknown to tamoxifen or observation following excision of recurrence. At a median follow-up of 11 years, DFS was longer with tamoxifen compared with observation alone with no difference in OS [36]. Her 2-positive recurrences should receive adjuvant anti-HER2-directed therapy.

Issues with Systemic Chemotherapy and Breast Reconstruction

Tamoxifen, the most commonly used hormonal agent for hormone-positive breast cancer, has also been associated with increased risk of microvascular flap complications in patients undergoing breast reconstruction. Several authors have examined the influence of chemotherapy on surgical outcomes of reconstructive surgery as well as eventual delay in starting chemotherapy caused by immediate reconstructive surgery. Furey et al. evaluated rate and severity of wound complications in 112 patients who received adjuvant chemotherapy after mastectomy with immediate breast reconstruction. The rate of wound complications (20.8% in the entire group) was similar in patients receiving chemotherapy when compared with a group of patients not receiving systemic treatment. No patient had delay in initiation of adjuvant therapy because of wound complications secondary to immediate reconstruction. The frequency of wound complications was also not increased in patients receiving adjuvant chemotherapy [37].

Caffo et al. examined concurrent use of adjuvant chemotherapy and immediate breast reconstruction (IBR) with skin expanders after mastectomy and compared the results with patients undergoing IBR without adjuvant chemotherapy and another group of patients undergoing mastectomy and chemotherapy but no IBR. The authors concluded that the interval between surgery and start of expander inflation was similar in two groups (median of 5 days) with no significant difference in complications in the patients receiving chemotherapy or not. Concurrent breast reconstruction and chemotherapy are therefore safe and feasible with no need for reduction in dose intensity [38].

Warren Peled et al. studied the impact of chemotherapy and timing of administration on postoperative outcomes in patients undergoing mastectomy and IBR. Although the adjuvant chemotherapy group had a higher rate of postoperative infections compared to the neoadjuvant and no chemotherapy group, the incidence of unplanned return to operating room and implant/expander removal was the same in three groups (26%, 22%, and 18% respectively, $p = 0.70$) [39].

Evaluating the delay in starting adjuvant chemotherapy caused by breast reconstructive surgery, Alderman et al. examined 3643 patients treated at eight different NCCN institutions. Patients undergoing BCS, mastectomy with immediate breast reconstruction (IBR), and mastectomy with delayed breast reconstruction (DBR) were evaluated for type of surgery and timing of chemotherapy. A significant delay (>8 weeks after surgery) was observed in 5.1% of cases. Factors that favored early start of chemotherapy were younger age, lower body mass, and absence of comorbidities. Overall, mastectomy with immediate breast reconstruction caused a modest but statistically significant delay in initiating systemic treatment [40].

In a prospective pilot study, Giacalone et al. compared the feasibility, oncologic safety, and esthetic outcome of skin-sparing mastectomy and immediate breast reconstruction (IBR) with LD flap and implant in selected patients undergoing surgery after neoadjuvant chemotherapy and radiotherapy ($N = 26$) with the more standard approach of mastectomy followed by adjuvant chemotherapy and radiotherapy and delayed breast reconstruction (DBR) with LD flap after completion of systemic treatment ($N = 78$). At a median follow-up of 4.1 years, early complications were seen in 61% of patients undergoing IBR vs. 56% in DBR. Capsular contracture, reconstruction failure, local recurrence, and cosmetic results were similar in both groups, suggesting safety of IBR even when performed after neoadjuvant chemotherapy or radiotherapy [41].

In a systematic review on delay in time to adjuvant chemotherapy caused by IBR, 14 studies with a total of 5270 patients were examined, 1942 patients underwent IBR while 3328 underwent mastectomy alone. One of the studies showed a shorter mean time to adjuvant chemotherapy after IBR (12.6 days), four studies showed a delay of 6.6–16.8 days while seven studies did not show any difference in time to chemotherapy after surgery. This systematic review suggested that IBR did not delay the start of chemotherapy to any clinically significant extent [42].

In conclusion, several series of patients reported in literature do not raise any major concern regarding association of chemotherapy and breast reconstruction. The time to start chemotherapy has not been significantly delayed by reconstructive surgery and there have been no reports of increased risk of infectious or surgical complications caused by neoadjuvant chemotherapy. Survival endpoints do not seem to be affected by the association of chemotherapy and reconstructive surgery.

Summary

Patients with locoregional recurrences after breast cancer present as a complex clinical challenge for multidisciplinary management. Surgery remains the main treatment modality for resectable locoregional recurrences. There is emerging role of redo BCS, redo SLNB, and re-irradiation supplemented with adjuvant systemic therapy depending on tumor stage and biology. Choice of treatment modality requires proper counseling and consideration of patient preference. Multidisciplinary tumor board plays a key role in management of these patients.

References

1. (2009) Management of Breast Cancer Recurrence. In: Sabel MS (ed) Essentials of breast surgery, first edn. Mosby Elsevier, 307–322
2. Van Tienhoven G, Voogd AC, Peterse JL et al (1999) Prognosis after treatment for loco-regional recurrence after mastectomy or breast conserving therapy in two randomized trials (EORTC10801 and DBCG-82TM). EORTC Breast Cancer Cooperative Group and the Danish Breast Cancer Cooperative Group. *Eur J Cancer* 35(1):32–38. [https://doi.org/10.1016/s0959-8049\(98\)00301-3](https://doi.org/10.1016/s0959-8049(98)00301-3)
3. Pisansky TM, Ingle JN, Schaid DJ et al (1993) Patterns of tumor relapse following mastectomy and adjuvant systemic therapy in patients with axillary lymph node-positive breast cancer. Impact of clinical, histopathologic, and flow cytometric factors. *Cancer* 72(4):1247–1260. [https://doi.org/10.1002/1097-0142\(19930815\)72:4<1247::aid-cnrcr2820720418>3.0.co;2-s](https://doi.org/10.1002/1097-0142(19930815)72:4<1247::aid-cnrcr2820720418>3.0.co;2-s). Erratum in: *Cancer* 1993 Oct 15;72(8):2524
4. Wadasadawala T, Vadgaonkar R, Bajpai J (2017) Management of isolated locoregional recurrences in breast cancer: a review of local and systemic modalities. *Cancer*. 17(7):493–502. <https://doi.org/10.1016/j.clbc.2017.03.008>
5. Voogd AC, van Oost FJ, Rutgers EJ, Elkhuisen PH, van Geel A, Scheijmans LJ, van der Slangen M, Botke G, Hoekstra CJ, Jobsen JJ, van de Velde C, von Meyenfeldt M, Tabak JM, Peterse JL, van de Vijver M, Coebergh JW, van Tienhoven G, Dutch Study Group on Local Recurrence after Breast Conservation (BORST Group) (2005) Long-term prognosis of patients with local recurrence after conservative surgery and radiotherapy for early breast cancer. *Eur J Cancer* 41(17):2637–2644. <https://doi.org/10.1016/j.ejca.2005.04.040>
6. Borner M, Bacchi M, Goldhirsch A, Greiner R, Harder F, Castiglione M, Jungi WF, Thürlimann B, Cavalli F, Obrecht JP (1994) First isolated locoregional recurrence following mastectomy for breast cancer: results of a phase III multicenter study comparing systemic treatment with observation after excision and radiation. Swiss Group for Clinical Cancer Research. *J Clin Oncol* 12(10):2071–2077. <https://doi.org/10.1200/JCO.1994.12.10.2071>
7. Halverson KJ, Perez CA, Kuske RR, Garcia DM, Simpson JR, Fineberg B (1992) Survival following locoregional recurrence of breast cancer: univariate and multivariate analysis. *Int J Radiat Oncol Biol Phys* 23(2):285–291. [https://doi.org/10.1016/0360-3016\(92\)90743-2](https://doi.org/10.1016/0360-3016(92)90743-2)

8. Dershaw DD, McCormick B, Osborne MP (1992) Detection of local recurrence after conservative therapy for breast carcinoma. *Cancer*. 70(2):493–496. [https://doi.org/10.1002/1097-0142\(19920715\)70:2<493::aid-cnrcr2820700219>3.0.co;2-3](https://doi.org/10.1002/1097-0142(19920715)70:2<493::aid-cnrcr2820700219>3.0.co;2-3)
9. McGale P, Taylor C et al (2014) Effect of radiotherapy after mastectomy and axillary surgery on 10-year recurrence and 20-year breast cancer mortality: meta-analysis of individual patient data for 8135 women in 22 randomized trials. *Lancet* 383(9935): 2127–2135. [https://doi.org/10.1016/S0140-6736\(14\)60488-8](https://doi.org/10.1016/S0140-6736(14)60488-8)
10. Isasi CR, Moadel RM, Blaufox MD (2005) A meta-analysis of FDG-PET for the evaluation of breast cancer recurrence and metastases. *Breast Cancer Res Treat* 90(2):105–112. <https://doi.org/10.1007/s10549-004-3291-7>
11. Faneyte IF, Rutgers EJ, Zoetmulder FA (1997) Chest wall resection in the treatment of locally recurrent breast carcinoma: indications and outcome for 44 patients. *Cancer*. 80(5):886–891
12. Pfannschmidt J, Geisbüsch P, Muley T, Hoffmann H, Dienemann H (2005) Surgical resection of secondary chest wall tumors. *Thorac Cardiovasc Surg* 53:234–239. <https://doi.org/10.1055/s-2005-837649>
13. Doyle T, Schultz DJ, Peters C, Harris E, Solin LJ (2001) Long-term results of local recurrence after breast conservation treatment for invasive breast cancer. *Int J Radiat Oncol Biol Phys* 51(1):74–80. [https://doi.org/10.1016/s0360-3016\(01\)01625-x](https://doi.org/10.1016/s0360-3016(01)01625-x)
14. Kurtz JM, Jacquemier J, Brandone H et al (1991) Inoperable recurrence after breast-conserving surgical treatment and radiotherapy. *Surg Gynecol Obstet* 172(5):357–361
15. Alpert TE, Kuerer HM, Arthur DW, Lannin DR, Haffty BG (2005) Ipsilateral breast tumor recurrence after breast conservation therapy: outcomes of salvage mastectomy vs. salvage breast-conserving surgery and prognostic factors for salvage breast preservation. *Int J Radiat Oncol Biol Phys* 63(3):845–851. <https://doi.org/10.1016/j.ijrobp.2005.02.035>
16. McCready DR, Fish EB, Hiraki GY et al (1992) Total mastectomy is not always mandatory for the treatment of recurrent breast cancer after lumpectomy alone. *Can J Surg* 35(5):485–488 Erratum in: *Can J Surg* 1992 Dec;35(6):641
17. Gentilini O, Botteri E, Veronesi P, Sangalli C, del Castillo A, Ballardini B, Galimberti V, Rietjens M, Colleoni M, Luini A, Veronesi U (2012) Repeating conservative surgery after ipsilateral breast tumor reappearance: criteria for selecting the best candidates. *Ann Surg Oncol* 19(12):3771–3776. <https://doi.org/10.1245/s10434-012-2404-5>
18. Poodt I, Walstra CJEF, Vugts G et al (2019) Low risk of development of a regional recurrence after an unsuccessful repeat sentinel lymph node biopsy in patients with ipsilateral breast tumor recurrence. *Ann Surg Oncol* 26(8):2417–2427. <https://doi.org/10.1245/s10434-019-07272-4>
19. Fisher B, Redmond C, Fisher ER, Bauer M, Wolmark N, Wickerham DL, Deutsch M, Montague E, Margolese R, Foster R (1985) Ten-year results of a randomized clinical trial comparing radical mastectomy and total mastectomy with or without radiation. *N Engl J Med* 312(11):674–681. <https://doi.org/10.1056/NEJM198503143121102>
20. De Boer R, Hillen HF, Roumen RM et al (2001) Detection, treatment and outcome of axillary recurrence after axillary clearance for invasive breast cancer. *Br J Surg* 88(1):118–122. <https://doi.org/10.1046/j.1365-2168.2001.01637.x>
21. Lukens JN, Vapiwala N, Hwang W-T, Solin LJ (2009) Regional nodal recurrence after breast conservation treatment with radiotherapy for women with early-stage breast carcinoma. *Int J Radiat Oncol Biol Phys* 73(5):1475–1481. <https://doi.org/10.1016/j.ijrobp.2008.06.1955>
22. Silverstein MJ, Savalia N, Khan S, Ryan J (2015) Extreme oncoplasty: breast conservation for patients who need mastectomy. *Breast J* 21(1):52–59. <https://doi.org/10.1111/tbj.12356>
23. Momoh AO, Ahmed R, Kelley BP, Aliu O, Kidwell KM, Kozlow JH, Chung KC (2014) A systematic review of complications of implant based breast reconstruction with pre reconstruction and post reconstruction radiotherapy. *Ann Surg Oncol* 21(1):118–124. <https://doi.org/10.1245/s10434-013-3284-z>
24. Williams JK, Bostwick J 3rd, Bried JT, Mackay G, Landry J, Benton J (1995) TRAM flap breast reconstruction after radiation treatment. *Ann Surg* 221(6):756–766. <https://doi.org/10.1097/0000658-199506000-00014>
25. Cordeiro PG, Snell L, Heerdt A, McCarthy C (2012) Immediate tissue expander/implant breast reconstruction after salvage mastectomy for cancer recurrence following lumpectomy/irradiation. *Plast Reconstr Surg* 129(2):341–350. <https://doi.org/10.1097/PRS.0b013e318205f203>
26. Lam TC, Hsieh F, Salinas J, Boyages J (2015) Can an immediate 2-stage breast reconstruction be performed after previous conservative surgery and radiotherapy? *Plast Reconstr Surg Glob Open* 3(7): e473. Published 2015 Aug 10. <https://doi.org/10.1097/GOX.0000000000000436>
27. Chetta MD, Aliu O, Zhong L, Sears ED, Waljee JF, Chung KC, Momoh AO (2017) Reconstruction of the irradiated breast: a national claims based assessment of postoperative morbidity. *Plast Reconstr Surg* 139(4):783–792. <https://doi.org/10.1097/PRS.00000000000003168>
28. Fischer JP, Basta MN, Shubinetz V, Serletti JM, Fosnot J (2016) A systematic meta-analysis of prosthetic-based breast reconstruction in irradiated fields with or without autologous muscle flap coverage. *Ann Plast Surg* 77(1):129–134. <https://doi.org/10.1097/SAP.0000000000000288>
29. O'Connell RL, Di Micco R, Khabra K et al (2018) Comparison of immediate versus delayed DIEP flap reconstruction in women who require post mastectomy radiotherapy. *Plast Reconstr Surg* 142(3): 594–605. <https://doi.org/10.1097/PRS.00000000000004676>
30. Clarke-Pearson EM, Chadha M, Dayan E, Dayan JH, Samson W, Sultan MR, Smith ML (2013) Comparison of irradiated versus non-irradiated DIEP flaps in patients undergoing immediate bilateral DIEP reconstruction with unilateral post mastectomy radiation therapy (PMRT). *Ann Plast Surg* 71(3):250–254. <https://doi.org/10.1097/SAP.0b013e31828986ec>
31. Taghizadeh R, Moustaki M, Harris S, Roblin P, Farhadi J (2015) Does post-mastectomy radiotherapy affect the outcome and prevalence of complications in immediate DIEP breast reconstruction? A prospective cohort study. *J Plast Reconstr Aesthet Surg* 68(10): 1379–1385. <https://doi.org/10.1016/j.jbps.2015.06.003>
32. Wahl AO, Rademaker A, Kiel KD, Jones EL, Marks LB, Croog V, McCormick BM, Hirsch A, Karkar A, Motwani SB, Tereffe W, Yu TK, Sher D, Silverstein J, Kachnic LA, Kesslering C, Freedman GM, Small W Jr (2008) Multi-institutional review of repeat irradiation of chest wall and breast for recurrent breast cancer. *Int J Radiat Oncol Biol Phys* 70(2):477–484. <https://doi.org/10.1016/j.ijrobp.2007.06.035>
33. Kauer-Dorner D, Pötter R, Resch A, Handl-Zeller L, Kirchheiner Mag K, Meyer-Schell K, Dörr W (2012) Partial breast irradiation for locally recurrent breast cancer within a second breast conserving treatment: alternative to mastectomy? Results from a prospective trial. *Radiother Oncol* 102(1):96–101. <https://doi.org/10.1016/j.radonc.2011.07.020>
34. Elkort RJ, Kelly W, Mozden PJ, Feldman MI (1980) A combined treatment program for the management of locally recurrent breast cancer following chest wall irradiation. *Cancer*. 46(4):647–653. [https://doi.org/10.1002/1097-0142\(19800815\)46:4](https://doi.org/10.1002/1097-0142(19800815)46:4)
35. Aebi S, Gelber S, Anderson SJ, Láng I, Robidoux A, Martín M, Nortier JW, Paterson AH, Rimawi MF, Cañada JM, Thürlimann B, Murray E, Mamounas EP, Geyer CE Jr, Price KN, Coates AS, Gelber RD, Rastogi P, Wolmark N, Wapnir IL, CALOR investigators (2014) Chemotherapy for isolated locoregional recurrence of

- breast cancer (CALOR): a randomized trial. *Lancet Oncol* 15(2): 156–163. [https://doi.org/10.1016/S1470-2045\(13\)70589-8](https://doi.org/10.1016/S1470-2045(13)70589-8)
36. Waeber M, Castiglione-Gertsch M, Dietrich D, Thürlimann B, Goldhirsch A, Brunner KW, Borner MM, Swiss Group for Clinical Cancer Research (SAKK) (2003) Adjuvant therapy after excision and radiation of isolated post mastectomy locoregional breast cancer recurrence: definitive results of a phase III randomized trial (SAKK 23/82) comparing tamoxifen with observation. *Ann Oncol* 14(8):1215–1221. <https://doi.org/10.1093/annonc/mdg347>
37. Furey PC, Macgillivray DC, Castiglione CL, Allen L (1994) Wound complications in patients receiving adjuvant chemotherapy after mastectomy and immediate breast reconstruction for breast cancer. *J Surg Oncol* 55(3):194–197. <https://doi.org/10.1002/jso.2930550313>
38. Caffo O, Cazzolli D, Scalet A, Zani B, Ambrosini G, Amichetti M, Bernardi D, Brugnara S, Ciaghi G, Lucenti A, Natale N, Agugiaro S, Eccher C, Galligioni E (2000) Concurrent adjuvant chemotherapy and immediate breast reconstruction with skin expanders after mastectomy for breast cancer. *Breast Cancer Res Treat* 60(3):267–275. <https://doi.org/10.1023/a:1006401403249>
39. Warren Peled A, Itakura K, Foster RD, Hamolsky D, Tanaka J, Ewing C, Alvarado M, Esserman LJ, Hwang ES (2010) Impact of chemotherapy on postoperative complications after mastectomy and immediate breast reconstruction. *Arch Surg* 145(9):880–885. <https://doi.org/10.1001/archsurg.2010.163>
40. Alderman AK, Collins ED, Schott A, Hughes ME, Ottesen RA, Theriault RL, Wong YN, Weeks JC, Niland JC, Edge SB (2010) The impact of breast reconstruction on the delivery of chemotherapy. *Cancer*. 116(7):1791–1800. <https://doi.org/10.1002/ncr.24891>
41. Giacalone PL, Rathat G, Daures JP, Benos P, Azria D, Rouleau C (2010) New concept for immediate breast reconstruction for invasive cancers: feasibility, oncological safety and aesthetic outcome of post-neoadjuvant therapy immediate breast reconstruction versus delayed breast reconstruction: a prospective pilot study. *Breast Cancer Res Treat* 122(2):439–451. <https://doi.org/10.1007/s10549-010-0951-7>
42. Harmeling JX, Kouwenberg CAE, Bijlard E et al (2015) The effect of immediate breast reconstruction on the timing of adjuvant chemotherapy: a systematic review. *Breast Cancer Res Treat* 153(2): 241–251. <https://doi.org/10.1007/s10549-015-3539-4>

Publisher's Note Springer Nature remains neutral with regard to jurisdictional claims in published maps and institutional affiliations.